



Case Report

## DUMBBELL SHAPED NEURILEMMOMA OF HAND

Shirol S S<sup>1\*</sup>, Kiran N G<sup>1</sup> and Geeta Nimbaragi<sup>2</sup>

\*Corresponding Author: **Shirol S S**, ✉ [ssshirol@yahoo.co.uk](mailto:ssshirol@yahoo.co.uk)

The occurrence of primary neural tumors in hand is relatively rare accounting for less than 5% of soft tissue tumors of hand. Neurilemmomas are the most common primary tumors among the peripheral nerve sheath tumors (Holdsworth, 1985; Phalen, 1976; Strickland et al., 1977; and Whitaker et al., 1976). Pre-operative diagnosis is possible in less than 1% of cases (Kehoe et al., 1995). Though dumbbell shaped tumors in spinal cord have been known to occur commonly, dumbbell shaped neurilemmoma of hand have not been reported. Here we report a case of dumbbell shaped neurilemmoma of hand with a small component above the palmar aponeurosis and large component deep to it, which was diagnosed pre-operatively with MRI and was successfully removed surgically with magnification.

**Keywords:** Dumbbell tumor, Hand tumor, Neurilemmoma, Schwannoma

### INTRODUCTION

Primary neural tumors of the hand and upper extremities are rare and represent less than 5% of soft tissue neoplasms of the upper extremities. Schwannomas are the most common primary solitary tumors among peripheral nerve tumours (Holdsworth, 1985; Phalen, 1976; Strickland et al., 1977; and Whitaker et al., 1976). Schwannomas are well-circumscribed, round or lobulated, benign tumors arising from Schwann cells, derived from the neural crest (White, 1967). The cause of these neoplasms is unknown. Neurilemmoma can be associated with von-Recklinghausen disease; when this is the case, multiple tumors often are

present. A Schwannoma is usually a solitary lesion, but multiple tumors are also reported (Kang et al., 2000; Patel et al., 1996; Tanabe et al., 1997; Tang et al., 1990; and White, 1967). Pre-operative differential diagnosis of these tumors is difficult and made in less than 1% of cases (Kehoe et al., 1995). The treatment is indicated either for cosmetic reasons or painful symptoms, and the treatment of choice is surgical excision under magnification (Artico et al., 1997; Donner et al., 1994; Kehoe et al., 1995; Ritt et al., 1991; Tang et al., 1990; and Whitaker et al., 1976). Here we present a neurilemmoma in the palm which was dumbbell shaped with a large deeper component which was successfully removed.

<sup>1</sup> Department of Plastic surgery, KLE University, Belgaum, Karnataka, India.

<sup>2</sup> Department of General Surgery, KLE University, Belgaum, Karnataka, India.

<sup>3</sup> Hospital Administrator, Belgaum, Karnataka, India.

## CASE REPORT

A 50 year old teacher presented with a painless swelling in the left palm for 20 years which was progressively increasing in size. He complained of severe unbearable pain in the swellings since 10 months and restricted and painful movements of the left hand fingers. There was no history of any hearing or visual disturbances and no headache. He visited different specialists where he was reassured and treated conservatively with no satisfactory results.

General physical examination was unremarkable. The swelling was 3 x 3 cms in size, spherical in shape occupying the center of palm, tender, firm, and immobile (Figures 1a and 1b). No sensory or motor deficits.

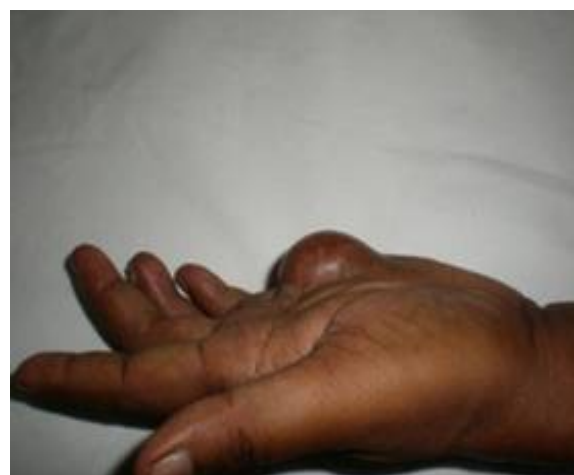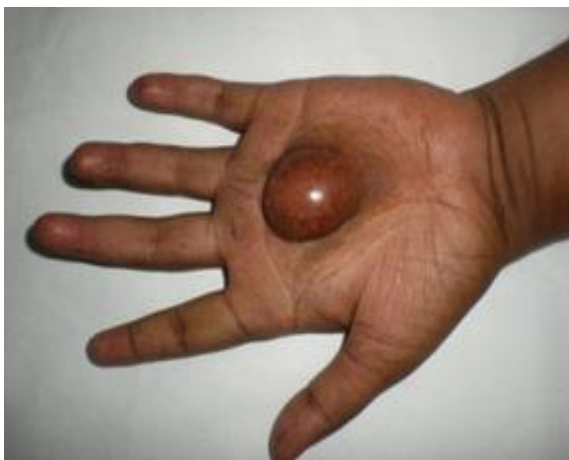MRI revealed dumbbell shaped tumor, T1 isointense and T2 mixes intense lesion in the palmar aspect of left hand with few cystic areas, approximately measuring 5.5 x 5.3 x 3.6. The lesion was seen to displace the tendons of flexor digitorum superficialis and flexor digitorum profundus anteriorly. Minimal posterior extension

of the lesion noted between shafts of third and fourth metacarpals. Anteriorly the fat plane between the lesion and subcutaneous tissue was lost. No obvious bone erosion or calcification was noted.

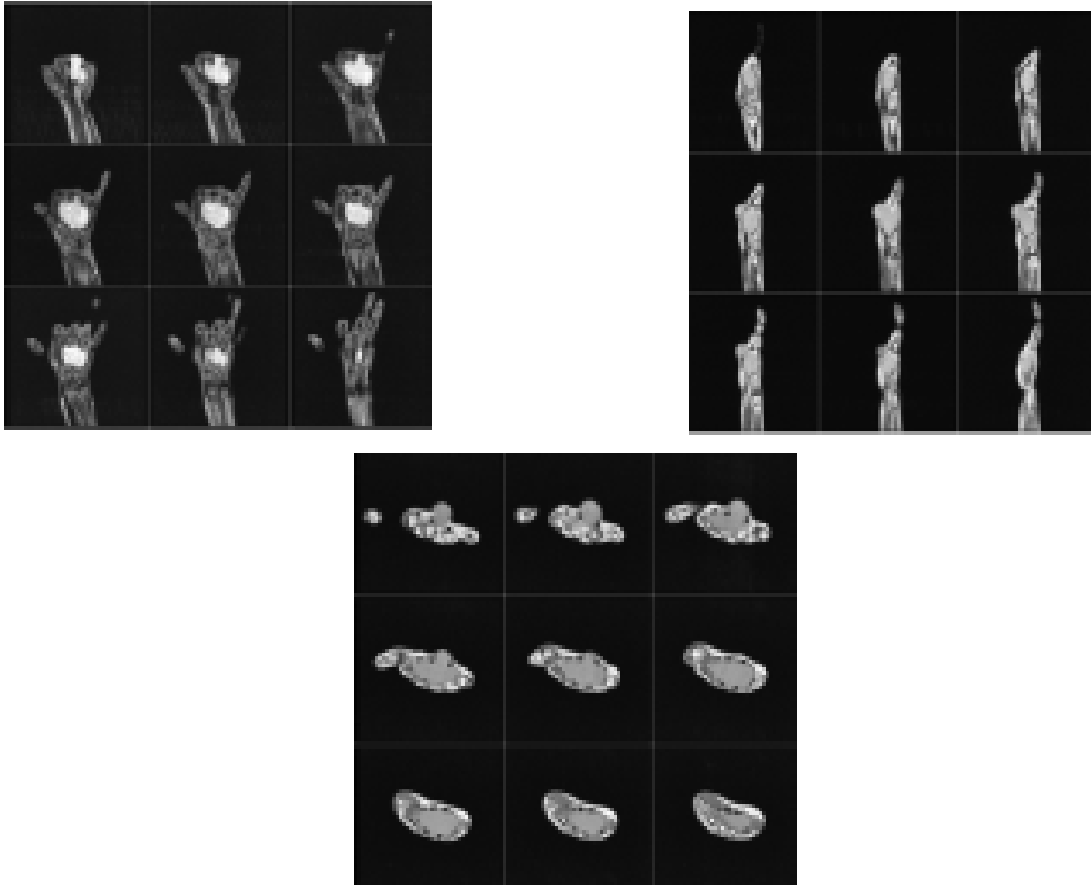
CT scan of the head was taken to rule out acoustic neuroma. With an incision parallel to the thenar crease the tumor was approached under general anaesthesia under tourniquet, and found to have a small tumor above the palmar aponeurosis and there was a large extension deeper to it typically like a dumbbell. The tumor had displaced the flexor tendons and adherent to the common digital nerve. Tumor was completely removed extracapsularly with loupe magnification preserving the nerve. Hemostasis achieved and closed in layers with suction drain in the cavity.

Biopsy revealed spindle cells showing interlacing pattern and palisading of nuclei, whorling pattern with Antoni A and Antoni B tissue suggestive of peripheral nerve neurilemmoma (Figures 4a and b).

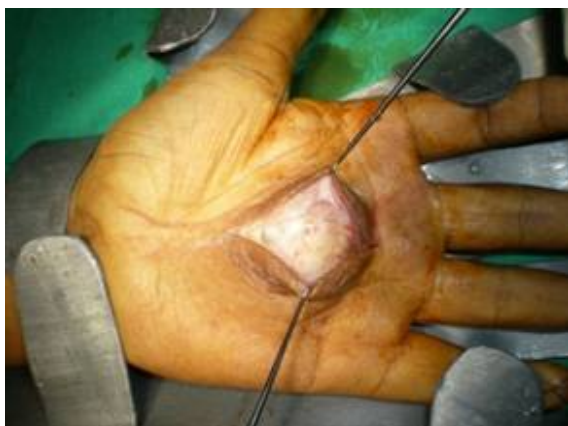**Figure 1a and 1b: Clinical Photograph of the Hand Shows Thin Stretched Hyperpigmented Skin Over The Lesion, The Metacarpophalangeal Joints in Extension**



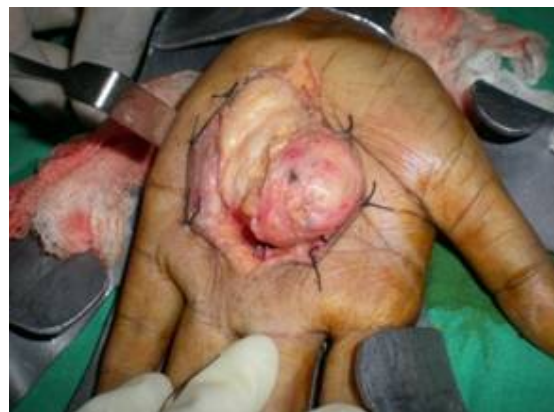**Figure 2a: Coronal Section of Left Hand Showing Tumor Extending from Base of to Head of 3<sup>rd</sup> and 4<sup>th</sup> Metacarpal; 2b: Sagittal Section of Hand Showing the Fat Plane Between the Lesion and Subcutaneous Tissue is lost; Figure 2c: Cross Section of hand Showing Tumor Extension from 2<sup>nd</sup> to 4<sup>th</sup> Metacarpal with Displacement of the Tendons of Flexor Digitorum Superficialis and Flexor Digitorum Profundus Anteriorly and Posterior Extension of the Tumor Between Shafts of Third and Fourth Metacarpals**



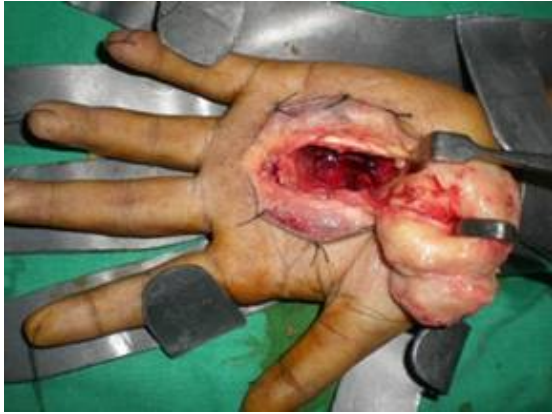**Figure 3a: Incision Taken from Base of Third Metacarpal to Distal Transverse Crease**



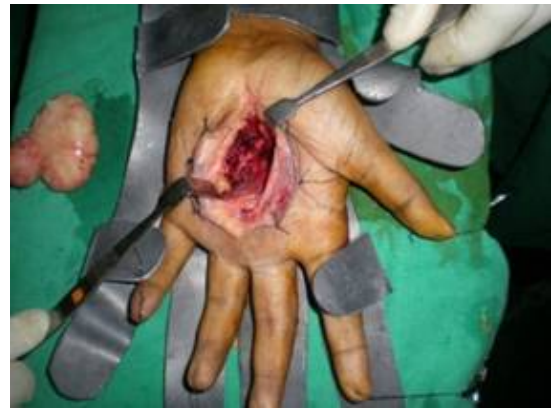**Figure 3b: Dissection Continued to Expose the Deeper Part of Tumor**



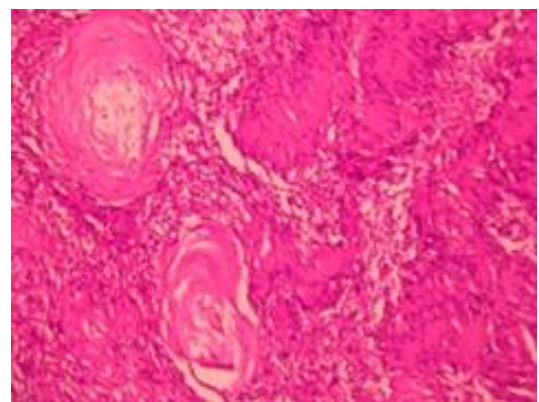
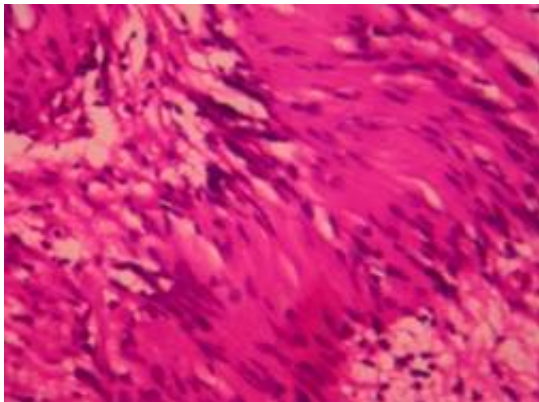
**Figure 3c: Final Stage of Dissection Where the Tumour is Delivered Out**



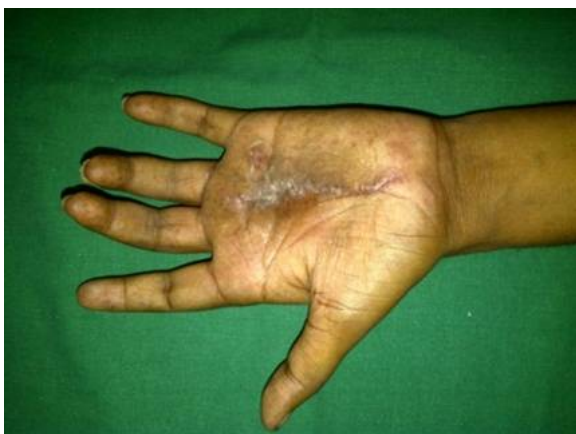**Figure 3d: Dumbbell Shaped Tumour with Large Deeper Part Can Be Seen with the Cavity in Hand**



**Figure 4a and 4b: Spindle Cells Showing Interlacing Pattern and Palisading of Nuclei, Whorling Pattern with Antoni A and Antoni B Tissue Suggestive of Peripheral Nerve Neurilemmoma**



**Figure 5: Six Months Follow up Clinical Photograph With Healed Scar and Good, Painless Finger Movements**



## RESULTS

At follow up after 6 months there was no recurrence, the suture line had healed well (Figure 5). Movement of left hand fingers was painless. The sensations were preserved. The patient is still on regular follow up.

## DISCUSSION

Though schwannomas are relatively rarer tumors of hand, they are common primary neural tumors (Holdsworth, 1985; Phalen, 1976; Strickland *et al.*, 1977; and Whitaker *et al.*, 1976). Dumbbell

tumors are described in the mediastinum, pelvis, spinal canal, abdomen and brain. Our literature search did not reveal any dumbbell tumor of hand. As these tumors are slow growing they are asymptomatic initially. Differential diagnosis clinically, when such a lesion appear in the hand is difficult. Kehoe *et al.*, (1995) reported correct pre-operative diagnosis in only one case of 88 pathologically confirmed schwannomas.

Hoglund *et al.* (1997) have reported 59% rate of correct diagnosis with ultrasonography while Ozdemir *et al.* (2005) reports it at 50%. HERNS *et al.* (1997) have described the role of MRI in imaging of peripheral nerve tumors. Despite being expensive, it helps in accurate localisation of the tumor and operative planning but is not accurate in differentiating schwannomas from malignant nerve sheath tumor.

Kececi *et al.* (1997) recommend extracapsular removal, while Ozdemir *et al.* (2005) recommend intracapsular removal. Ozdemir *et al.* (2005) have reported long term results of 14 cases of Schwannomas with a mean follow up period of 12.6 years.

## CONCLUSION

Schwannomas presenting as dumbbell tumor in the hand has not been reported in the literature. With microsurgical dissection it is possible to achieve complete tumor safely and without recurrence.

## ACKNOWLEDGMENT

Special thanks to Dr. Yenni V.V and Dr. Mahesh Prabhu for their continued moral support in preparing this manuscript.

## REFERENCES:

1. Artico M *et al.* (1997), "Benign Neural Sheath Tumours of Major Nerves: Characteristics in 119 Surgical Cases", *Acta Neurochir (Wien)* Vol. 139, pp. 1108-1116.
2. Donner T R *et al.* (1994), "Neural Sheath Tumors of Major Nerves", *J Neurosurg*, Vol. 81, pp. 362-373.
3. HERNS *et al.* (1997), "The Role Of Magnetic Resonance Imaging In The Management Of Peripheral Nerve Tumors", *J Hand Surg Br*, Vol. 22, No. 1, pp. 57-60.
4. Hoglund M *et al.* (1997), "A Statistical Model for Ultrasound Diagnosis of Soft-tissue Tumours in the Hand and Forearm", *Acta Radiol.*, Vol. 38, pp. 355-358.
5. Holdsworth B J (1985), "Nerve Tumours in the Upper Limb. a Clinical Review", *J Hand Surg Br.*, Vol. 10, pp. 236-238.
6. Kang H J *et al.* (2000), "Schwannomas of the Upper Extremity", *J Hand Surg Br.*, Vol. 25, pp. 604-607.
7. Kececi Y *et al.* (1997), "Benign Giant Schwannoma Located In The Upper Arm", *Ann Plast Surg.*, Vol. 39, pp. 100-102.
8. Kehoe N J *et al.* (1995), "Solitary Benign Peripheral-nerve Tumours. Review of 32 Years' Experience", *J Bone Joint Surg Br.*, Vol. 77, pp. 497-500.
9. Ozdemir O *et al.* (2005), "Schwannomas of the Hand and Wrist: Long Term Results and Review of Literature", *Journal of Orthopaedic Surgery*, Vol. 13, No. 3, pp. 262-272.

10. Patel M R *et al.* (1996), "Multiple Schwannomas Of The Ulnar Nerve: A Case Report", *J Hand Surg Am.*, Vol. 21, pp. 875-876.
11. Phalen G S (1976), "Neurilemmomas of the Forearm and Hand", *Clin Orthop Relat Res.*, Vol. 114, pp. 219-222.
12. Ritt M J *et al.* (1991), "A Very Large Neurilemmoma of the Anterior Interosseous Nerve", *J Hand Surg Br.*, Vol. 16, pp. 98-100.
13. Strickland J W *et al.* (1977), "Nerve Tumors of the Hand and Forearm", *J Hand Surg Am.*, Vol. 2, pp. 285-291.
14. Tanabe K *et al.* (1997), "Multiple Schwannomas in the Radial Nerve", *J Hand Surg Br.*, Vol. 22, pp. 664-666.
15. Tang J B, Ishii S, Usui M, Naito T (1990), "Multifocal Neurilemmomas in Different Nerves of the Same Upper Extremity", *J Hand Surg Am.*, Vol. 15, pp. 788-792.
16. Whitaker W G *et al.* (1976), "Benign Encapsulated Neurilemmoma: A Report of 76 Cases", *Am Surg.*, Vol. 42, pp. 675-678.
17. White N B (1967), "Neurilemmomas of the Extremities", *J Bone Joint Surg Am.*, Vol. 49, pp. 1605-1610.